Luigi Canullo
Roberto Cocchetto
Ignazio Loi

PERI-IMPLANT TISSUE REMODELING

SCIENTIFIC BACKGROUND & CLINICAL IMPLICATIONS

Quintessenza Edizioni
Milan, Berlin, Chicago, Tokyo, Barcelona, Istanbul, London, Moscow, New Delhi, Paris, Beijing, Prague, São Paulo, Seoul, Warsaw

Foreword

This textbook, with more than 20 contributing authors, covers topics ranging from basic aspects of implant dentistry all the way to the most modern concepts of platform switching, immediate implant placement, and the application of piezoelectric surgery.

A well-documented introductory chapter discusses the various aspects and risks affecting bone modeling and remodeling. Patient-related systemic and local factors are identified and evaluated. Three conditions that affect peri-implant bone remodeling, namely systemic, local, and surgical factors, are described.

In a more clinical second chapter, flap design and peri-implant tissue stability are discussed in the light of the concept of the biotype and the biologic width. The third chapter presents the novel concept of minimally invasive implant site preparation, applying piezoelectric surgical techniques.

Three comprehensive chapters are devoted to the platform-switching concept. This is dealt with from both a theoretical as well as a practical point of view. Emphasis is placed on the histologic consequences of this concept. In addition, many studies that use finite element analysis to describe the effects of platform switching on the marginal bone levels around implants are presented; however, the reader should keep in mind that finite element analysis cannot reflect such biologic phenomena owing to the fact that bone as a living tissue does not follow the mathematic rules that are applied with finite element analysis.

Chapter 7 covers the topic of peri-implant bone remodeling around implant-abutment connections. Chapter 8 is devoted to the prosthetic aspects of implant dentistry. Design of preparations as well as aspects of finish lines and emergence profiles are presented in a comprehensive way, and pertinent issues are addressed. The clinical concept of a shoulderless abutment is discussed. The chapter is illustrated with relevant clinical cases to support specific concepts.

Chapter 9 presents the role of prosthetic protocols on peri-implant stability. Biologic, technical, and clinical aspects are discussed together. Significant attention is given to provisionalization and to patient-centered aspects such as scheduling and reduction of discomfort during prosthetic rehabilitation. Finally, the last chapter is devoted to titanium as a material of choice for implant dentistry. Emphasis is given to the cleaning of titanium surfaces as a prerequisite for optimal function.

In summary, this new book by Luigi Canullo and his coworkers provides an implant dentistry treatment concept that includes platform switching and strict prosthetic guidance to reach optimal treatment outcomes. The book is written in a lucid way and may be recommended to all colleagues who are involved in implant dentistry.

Niklaus P. Lang, DMD, MS, PhD, Dr Odont
Department of Periodontology and Implant Dentistry
Prince Philip Dental Hospital
Comprehensive Dental Care, Implant Dentistry
The University of Hong Kong
Hong Kong SAR

Authors

Luigi Canullo, DDS, PhD, graduated cum laude in dentistry and prosthodontics at the Sapienza University of Rome, Italy, in 1994 before turning his attention to surgical techniques in implant dentistry. He attended postgraduate courses in Italy and abroad (University of California, Los Angeles [UCLA]), and completed his doctorate at the University of Bonn, Germany. Dr Canullo lectures extensively on surgical and prosthetic aspects of implant dentistry; was a visiting professor at the Sacred Heart University in Bauru, Brazil; and has authored several journal articles on implantology topics. He is a member of the Società Italiana di Ossigeno (SIO) and the European Academy of Osseointegration (EAO) and was awarded the EAO 2008 Clinical Research Award. Dr Canullo maintains a private practice in Rome, Italy, limited to surgery and implant-supported prosthetic rehabilitation.

Roberto Cocchetto, DDS, MD, graduated in medicine and surgery before specializing in dentistry and prosthodontics at the Verona University, Italy. As a professor, he has taught postgraduate courses in advanced implant treatment at the University of Udine and the University of Chieti in Italy. Dr Cocchetto has dedicated his professional interests to implant prosthodontics and surgery and has been involved in several clinical studies on peri-implant bone preservation and immediate loading. He is the author of several journal articles, including a recent original prosthetic protocol for implant-supported restorations, and is an internationally recognized speaker. Dr Cocchetto is an honorary member of the Advanced Implantology Study Group (AISG) and maintains a private practice in Verona, Italy.

Ignazio Loi, DDS, MD, graduated in medicine and surgery before specializing in dentistry and prosthodontics at the University of Cagliari, Italy. He is a member of the Associazione Italiana Ospedalità Privata (AIOP) and an honorary member of the Advanced Implantology Study Group (AISG). Dr Loi maintains a private practice in Cagliari, Italy.

Table of Contents

Chapter 1

Factors Affecting Peri-Implant Bone Remodeling **1**

Patient-Related Factors 2

Local Factors 4

Surgical Factors 7

Implant-Related Factors 9

Biologic Factors 11

Prosthetic Factors 12

Biomechanical Factors 14

Conclusions 14

Acknowledgments 15

Chapter 2

Flap Design and Peri-Implant Tissue Stability **25**

Biotype and Thickness of Soft Tissues 26

Diagnosis, Planning, and Flap Design 28

Conclusions 45

Chapter 3

Piezoelectric Bone Surgery **49**

Implant Osteotomies 51

Chapter 4

Platform switching **57**

Biometric Evaluation of the Platform-Switching Concept 59

Microbiologic Evaluation and Inflammatory Reaction to Platform Switching 64

Chapter 5
Histologic Aspects of Platform Switching **75**
Formation of the Tissue-Implant Interface 75
Histomorphogenesis of Soft Tissues Around Matching Abutments and Implants 76
Histomorphogenesis of Soft Tissues Around Platform-Switched Implants 79
Dimension of the Biologic Width Around Platform-Switched Implants 83
Conclusions 88

Chapter 6
Biomechanical Aspects of Platform Switching **91**
Biomechanical Aspects of Platform Switching 92
Finite Element Analysis 93
Conclusions 98

Chapter 7
Implant-Abutment Connections and Peri-Implant Bone Remodeling **101**
Implant Connection Configurations 102
Proposed Changes in Connection Design 104
Conclusions 104

Chapter 8
Abutment Morphology and Peri-Implant Soft Tissue **107**
Finish Line 107
Emergence Profile 111
From Teeth to Implants: The Shoulderless Abutment 116
Clinical Case 120
Conclusions 125

Chapter 9
The Role of Prosthetic Protocols in Peri-Implant Tissue Stability **127**
Minimally Invasive Prosthetic Protocol 128
The Shoulderless One-Abutment Protocol 133
Clinical Case 134
Conclusions 145

Chapter 10
Future Perspectives: Plasma Cleaning **149**

If the alveolar bone measures less than 1.5 mm in thickness, it should be increased by performing the appropriate surgical procedures. In cases where the convex profile of radicular bone is also required, it may be achieved by grafting bone tissue or connective tissue in the deficient areas.

The following conditions may occur from a clinical point of view:

- Sufficient usable bone, adequate esthetic volume, and thick gingival biotype
- Sufficient usable bone, inadequate esthetic volume, and thick gingival biotype
- Sufficient usable bone, inadequate esthetic volume, and thin gingival biotype
- Insufficient usable bone

Sufficient usable bone, adequate esthetic volume, and thick gingival biotype

Clinically, the optimal conditions for a successful outcome are crestal bone thickness > 6 mm, dense and thick soft tissue, and abundant keratinized gingiva. If the dental alveolar proportions (evidenced by means of the radiographic stent) are also satisfactory, minimal surgical access (flapless surgery) is advisable since no tissue modifications are required.
A flapless incision[13] can be made (Fig 2-5) by means of a mucosal or a tooth-form incision.[39] Alternatively, in order to preserve interdental papillae, surgeons may use a trapezoidal flap. This can be accomplished by making a horizontal palatal (or lingual) incision the same width as the implant and two minimal diverging incisions reaching the facial side of the edentulous site. The incision must remain at least 1 mm distant from the margin of the papillae. This flap design spares the interdental papillae and minimizes adverse effects on the underlying bone. It is the authors' opinion that a single-stage surgical protocol is indicated in all patients presenting with ideal soft and hard tissues.

Fig 2-5
(a to c) Preoperative photographs of a female patient with a hopeless maxillary premolar. *(d to f)* After minimally invasive extraction, a socket preservation procedure was performed, using a nanostructured magnesium-enriched hydroxyapatite and collagen sponge.

Fig 2-5 [cont]
(g and h) A resin-bonded partial denture was used to stabilize the graft. *(i and j)* Soft tissue response 4 months after extraction. *(k)* The CT scan identified sufficient usable bone with adequate esthetic volume in this edentulous site. The surgeon planned this treatment using CT scanning and a radiographic stent. The case was planned so that the implant had at least 2 mm of alveolar bone surrounding the implant after placement. In order to preserve the tissue volume as much as possible, the surgeon decided on a flapless implant placement protocol. *(l)* The tooth-supported surgical guide in place. The hollow metal tube in the surgical guide allowed the initial drill insertion. *(m)* The osteotomy was enlarged. *(n and o)* The implant was placed with insertion torque greater than 35 Ncm. *(p)* Impression coping abutment in place on the implant. Rubber dam was placed over the implant to prevent peri-implant tissue contamination. The surgical guide was connected to the coping and used to create a working cast with an implant analog. A stock abutment was prepared on the master cast just as the implant was placed. A provisional crown was fabricated directly on the prepared abutment in the master cast. *(q)* The prepared abutment in place on the implant. The prepared abutment was placed immediately after the implant was placed in order to avoid the traumas associated with conventional prosthodontic implant procedures. *(r)* The provisional crown in place on the prepared titanium abutment.

Fig 4-12 [cont]
(g and h) Soft and hard tissue response at the 2-year follow-up appointment.

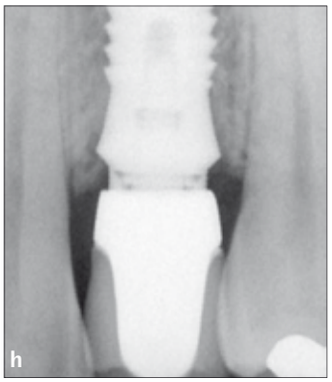

The effect of a rough-surfaced implant and platform switching was analyzed in a recently published randomized controlled study[19]; the mean follow-up times were at least 2 years. The study compared traditionally restored implants with platform-switched implants and reported that immediate restorations with platform switching provided peri-implant hard tissue stability, even in immediate postextraction implant restorations.

Fig 4-12 [cont]
(i to k) Soft and hard tissue response at the 7-year follow-up appointment.

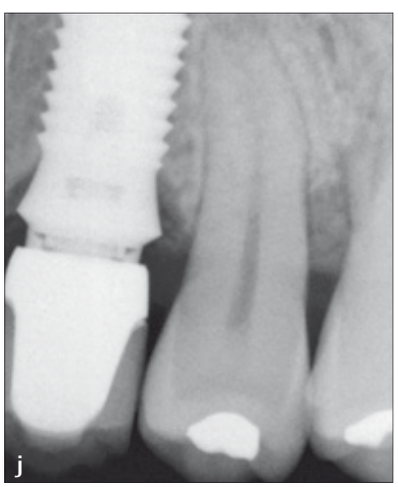

In the test group, a radiographic analysis showed mean bone resorption of 0.30 mm (SD, 0.16 mm). This mean value was statically significantly different ($P \leq .005$) when compared with the control group (mean, 1.19 mm; SD, 0.35 mm).

The same differences have been clinically replicated by the author.[20] Implants restored using the platform-switching concept showed stable tissue levels after 2 years and, in some cases, minimal gain in papilla and soft marginal tissues (Fig 4-13). The mean values were statistically significantly different ($P \leq .005$) compared with the control group, where soft tissue recession was always noted.

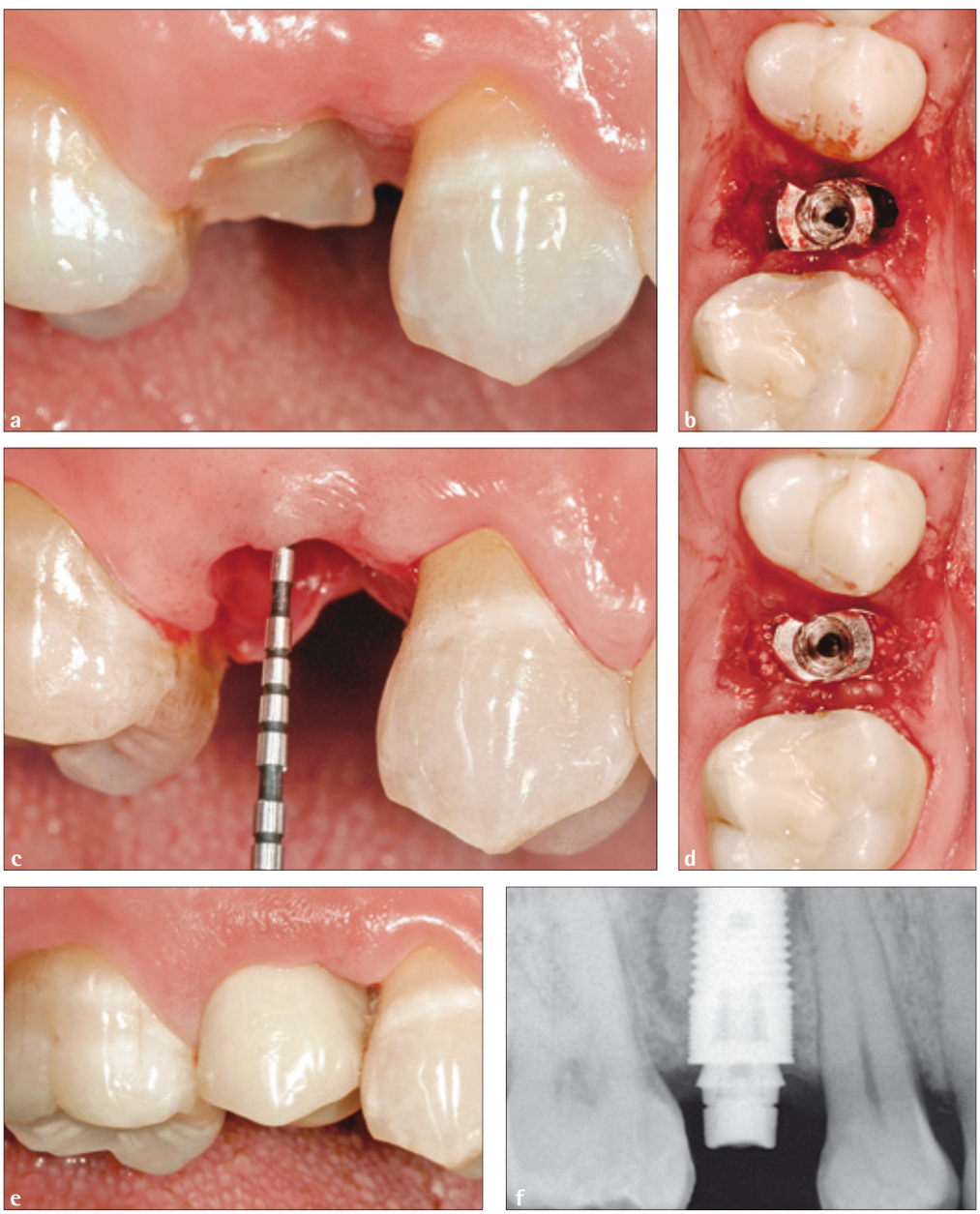

Fig 4-13
(a) Hopeless tooth extracted with a minimally invasive procedure. *(b)* Soft tissue measurement and bone buccal margin mapping to detect preoperative defects. *(c)* Totally rough surfaced implant placement. *(d)* Filling of the gaps between the implant and the bony walls. *(e and f)* Soft and hard tissue response at the time the provisional restoration was placed, immediately after implant insertion. Note that the mesial papilla was missing.

Fig 8-5
(a and b) The gull wing profile in flat gingival contours.

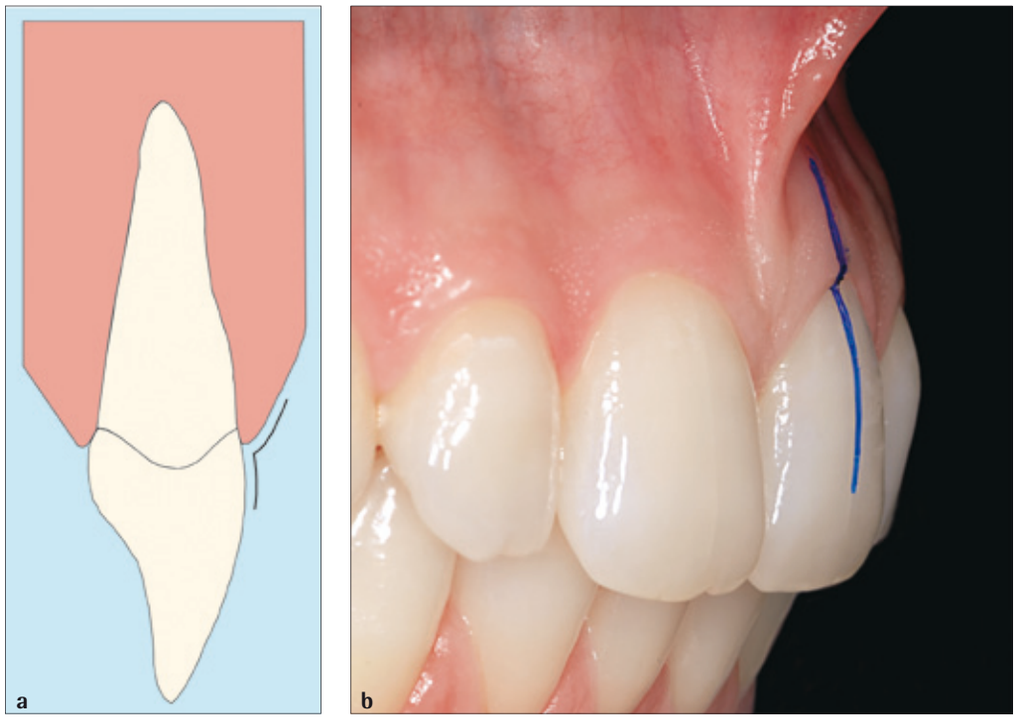

Fig 8-6
(a and b) The gull wing profile in convex gingival contours.

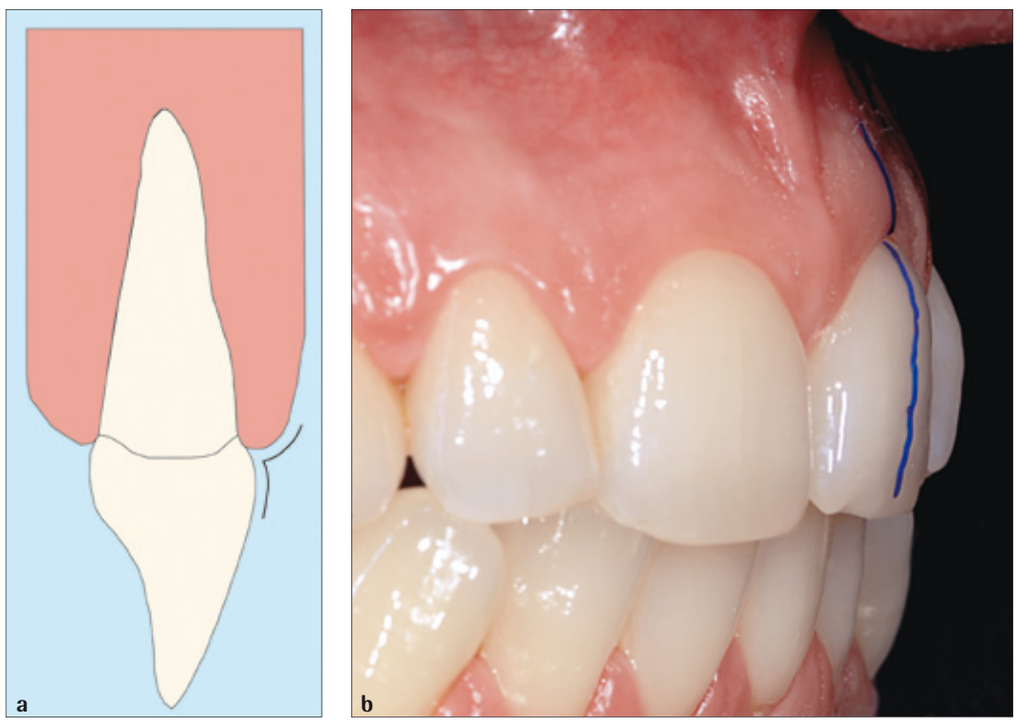

The new contour is then refined (Fig 8-7f), and it should be noted that even when the bur is used on the metal collar, it will not affect the marginal adaptation of the crown as it would with any defined shoulder or chamfer margin preparation. The crowns are then glazed and polished (Figs 8-7g and 8-7h). Clinically, the soft tissues will adapt to the restoration's emergence profiles, whose designs have been chosen exclusively on esthetic parameters (Fig 8-7i).

Fig 8–7
(a) Four maxillary incisor crowns after the first firing on the working cast without the gingival contours. *(b)* The crowns do not fit on the cast with the flat gingival contours. *(c)* Marginal gingiva is removed to create an ideal esthetic outline. *(d and e)* The space between the gingiva and crowns is filled with ceramic. *(f)* The contour is finished with a diamond bur.