

Advanced Immediate Loading

Georgios E. Romanos, DDS, PhD, Prof Dr med dent

Professor and Associate Dean for Clinical Affairs
School of Dental Medicine
State University of New York at Stony Brook
Stony Brook, New York

Professor of Oral Surgery and Implant Dentistry
Dental School Frankfurt (Carolinum)
Johann Wolfgang Goethe University
Frankfurt, Germany



Quintessence Publishing Co, Inc

Chicago, Berlin, Tokyo, London, Paris, Milan, Barcelona, Istanbul,
São Paulo, New Delhi, Moscow, Prague, and Warsaw

Contents

Dedication	<i>ix</i>
Foreword	<i>x</i>
Preface	<i>xi</i>
Contributors	<i>xii</i>

1 Bone Biology and Osseointegration of Dental Implants *1*

Basic Bone Anatomy
Bone Remodeling
Bone Microvasculature
Bone Physiology
Strain Detection and Mechanotransduction
Bone Healing
Clinical Considerations
Conclusion

2 Basic Principles and Clinical Applications of Immediate Loading *11*

Definition of Immediate Loading
Rationale for Immediate Loading
Clinical Treatment Concepts with Immediate Loading
Requirements for Successful Immediate Loading
Clinical Considerations
Conclusion

3 Role of the Implant Surface in Immediate Loading *27*

Osseointegration and the Implant Surface
Testing of Implant Surface Designs
Surface Modification of Dental Implants
Conclusion

4	Role of Implant Design in Immediate Loading	39
	Types of Implant Stability	
	Micromovement at the Bone-Implant Interface	
	Conclusion	
5	Histologic Evaluation of Immediately Loaded Implants	43
	Animal Studies	
	Human Studies	
	Conclusion	
6	Immediate Loading in the Anterior Mandible Using Overdentures	55
	Immediate Loading in the Edentulous Patient	
	Immediate Loading with Telescopic Abutments in the Partially Edentulous Patient	
7	Immediate Loading in Edentulous Jaws	63
	Case Reports	
	Guidelines for a Successful Immediate Loading Protocol in Edentulous Arches	
	Diet Protocol for Patients with Immediately Loaded Implants	
8	Immediate Loading in Posterior Regions	79
	Posterior Maxilla	
	Posterior Mandible	
	Conclusion	
9	Immediate Loading in Grafted Bone	89
	Case Reports	

10	Immediate Loading in Immunocompromised Patients	107	
	Heavy Smokers		
	HIV-Positive Patients		
	Conclusion		
11	Immediate Loading with Simultaneous Sinus Elevation	121	
	Case Reports		
12	Immediate Loading of Single-Tooth Implants		131
	Case Reports		
13	Immediate Loading of Implants Placed in Fresh Extraction Sockets	145	
	Extraction Socket Healing and Tissue Preservation		
	Implant Placement in Fresh Extraction Sockets		
	Considerations for Clinical Application of the Protocol		
	Case Reports		
	Conclusion		
14	Management of Immediate Loading Complications	173	
	Surgical Complications		
	Prosthetic Complications		
	Conclusion		
	Index	177	

Dedication



*In loving memory of my parents, Rallou and Evangelos Romanos,
who nurtured my passion for science and instilled in me the value of hard work.*

Foreword

I am delighted to be asked to write the foreword for this new book on advanced immediate loading of dental implants. This book is greatly needed, and I am especially glad that Dr Georgios Romanos decided to undertake this work to provide the dental profession with an important resource on implant dentistry.

It is hard to believe that more than 30 years have gone by since the group at Harvard organized the landmark National Institutes of Health–Harvard Consensus Development Conference on Dental Implants. In June of 1978, a group of clinicians and investigators assembled in Boston to (1) examine the evidence that dental implants “work”; (2) determine the risks and benefits of placing dental implants; and (3) establish the rules for implant placement, postoperative wound healing, and implant loading. Although the conclusions reached during this conference were positive, those were nonetheless tentative days for the field of implant dentistry. We were still to some extent “flying by the seat of our pants” in the management of our patients with dental implants. But clearly the field of implant dentistry has come a long way since that time.

Over the ensuing 33 years, we have seen implant designs greatly change, such that now state-of-the-art root-form implants are standard practice. We have watched as biomaterials engineers have perfected implant surfaces to foster maximum osseointegration between device and bone. Periodontal and oral surgeons have taught us how to gain much-needed bone in sites prior to implant placement by using bone grafts, membranes, signaling molecules, and novel surgical techniques. But perhaps most surprisingly, restorative colleagues continue to teach us that, in certain clinical situations, dental implants can be restored and placed into function almost immediately, and if not immediately, then very soon after implant placement.

Now, to complicate things even more, we are learning that individuals with untreated periodontitis have a greater risk for certain systemic illnesses such as car-

diovascular disease, diabetes, adverse pregnancy outcomes, and pulmonary disease. Thus, dentistry is asking at what point should a tooth with advanced periodontitis be extracted and replaced with a dental implant.

In the last 15 years, a number of excellent books on implant dentistry have been published. Written by outstanding clinicians, these books cover many aspects of dental implants, but it is evident that there has not been a good assembling of the evidence to show that, following implant placement in a variety of situations, implants may be immediately loaded. Clearly, this is something that has been on people’s minds for some time. One cannot attend a conference on dental implants without hearing about the advantages, disadvantages, indications, and contraindications for immediate loading of implants. And so, Dr Romanos’ book is very timely and much needed.

Dr Romanos has assembled an excellent group of players for this book. Equally notable are the topics covered in this book; Dr Romanos covers the field thoroughly. This book is an excellent resource for patient management, with each chapter focusing on very specific issues that confront clinicians every day.

All told, I say “lucky us.” We now have a first-rate book that provides another area in the multiple facets of management of our patients with dental implants; that is, the treatment planning and management of implants that are immediately loaded. I look forward to the coming years in the development of the field of implant dentistry knowing that clinicians such as Dr Romanos and his colleagues will help to continually advance this very exciting area of dentistry.

Ray C. Williams, DMD

Professor and Dean
School of Dental Medicine
State University of New York at Stony Brook
Stony Brook, New York

Preface

Today, there are many books that cover the immediate loading of dental implants. This textbook and color atlas has a primary goal of providing clinicians and researchers with current information about the concepts of immediate functional loading when using different implant systems and surfaces.

I have tried to review the most significant studies in the current literature related to immediately loaded implants. The featured treatment protocols for immediate loading using the classical indications with cross-arch stabilization are demonstrated step by step. The histologic proof of this concept is the focus of a chapter that elaborates both previous animal studies as well as human histology to explain bone biology under occlusal loading forces. The reader is able to review the basic biology of the remodeling process and understand its role in immediate functional loading as well as in protocols for delayed and immunocompromised wound healing. I have also presented additional prosthetic concepts for the use of removable implant-supported restorations in conjunction with an immediate prosthesis, which is especially important for elderly patients and patients with special needs.

The inclusion of more advanced surgical techniques using lateral and vertical bone augmentation—including the sinus augmentation—with simultaneous implant placement and immediate functional loading illustrates one of the main areas of focus of this book. Long-term data is included as evidence of the viability of these advanced treatment protocols. The placement of implants in fresh extraction sockets and immediate restoration with simultaneous bone augmentations are illustrated in detail. The clinical scenarios are presented within the

context of a biologic approach to both eliminate postoperative complications and further new principles in implant dentistry. The final chapter of this book addresses the complications with immediate loading concepts and discusses their solutions.

Because I am its primary author, this book presents clinical and research experience of the last 15 years of my clinical and academic career, throughout which I have been using advanced concepts of immediate functional loading in implant dentistry. I am also proud that I had the opportunity to work closely and collaborate with some of the best clinicians and researchers in Europe, Asia, South America, and the United States, many of whom have become my close friends and continue to inspire me in their work. Thus, I have also selected additional experts to contribute their advanced experience in the areas of wound healing and implant surfaces as well as to present representative clinical examples from their daily practice.

The production of this book has been performed with high precision and excellence by the group at Quintessence Publishing under the editorial guidance of Bryn Grisham and the leadership of Bill Hartman and Lisa Bywaters. I would also like to express special thanks to Christian Haase and his father, Dr h.c. Horst-Wolfgang Haase, who have supported my vision from the first.

Finally, there is no doubt in my mind that a book like this would not be possible without the support, continuous encouragement, and patience of my wife, Dr Enisa Begic Romanos. I would like to thank her so much for her love and her vision to make my dream a reality.

—*Georgios E. Romanos, DDS, PhD, Prof Dr med dent*

Contributors

Camila Cinto Arita, DDS

Private Practice
Ribeirao Preto, São Paulo, Brazil

César Augusto Arita, DDS, MSc, PhD

Private Practice
Ribeirao Preto, São Paulo, Brazil

Estevam A. Bonfante, DDS, MSc, PhD

Department of Prosthodontics
Bauru School of Dentistry
University of São Paulo
Bauru, São Paulo, Brazil

Paulo G. Coelho, DDS, PhD

Assistant Professor
Department of Biomaterials and Biomimetics
New York University College of Dentistry
New York, New York

Jeffrey Ganeles, DMD

Clinical Associate Professor
College of Dental Medicine
Nova Southeastern University
Fort Lauderdale, Florida

Private Practice
Boca Raton, Florida

Jack E. Lemons, PhD

Professor
Department of Prosthodontics
School of Dentistry
University of Alabama at Birmingham
Birmingham, Alabama

Dittmar May, DMD, MD, Dr med dent

Oral and Maxillofacial Surgeon
Practice Limited to Implant Surgery
Lunen, Germany

Jose M. Navarro, DDS, MS

Private Practice
Las Palmas, Spain

Adriano Piattelli, DDS, MD, PhD

Professor
Department of Oral Pathology and Medicine
School of Dentistry
University of Chieti-Pescara
Chieti, Italy

Georgios E. Romanos, DDS, PhD, Prof Dr med dent

Professor and Associate Dean for Clinical Affairs
School of Dental Medicine
State University of New York at Stony Brook
Stony Brook, New York

Professor of Oral Surgery and Implant Dentistry
Dental School Frankfurt (Carolinum)
Johann Wolfgang Goethe University
Frankfurt, Germany

Nigel A. Saynor, BDS

Private Practice
Stockport, England

Karl Andreas Schlegel, MD, DDS, PhD, Prof Dr med dent

Professor
Department of Oral and Maxillofacial Surgery
University of Erlangen-Nürnberg
Erlangen, Germany

Nelson R. F. A. Silva, DDS, MS, PhD

Assistant Professor
Department of Prosthodontics
Department of Biomaterials and Biomimetics
New York University College of Dentistry
New York, New York

Tonino Traini, DDS, PhD

Section of Prosthodontics
Department of Oral Sciences, Nano,
and Biotechnologies
School of Dentistry
University of Chieti-Pescara
Chieti, Italy

Basic Principles and Clinical Applications of Immediate Loading

2

Implant survival is associated with implant stability during loading. Implant osseointegration is a prerequisite to establishing long-term stability. This may be promoted by using implant designs that allow primary anchorage of the implant in the surrounding bone as well as minimizing inflammatory reactions during healing.

According to empiric methods, healing periods of 3 months for the mandible and 6 months for the maxilla are required prior to loading an implant; however, this has not been confirmed by experiments.¹⁻³ A period without loading is considered part of the standard protocol for successful osseointegration. Initial biomechanical forces exerted on implants are linked to the formation of connective tissue at the bone-implant interface.⁴⁻⁷ If implants are initially stable but have not yet undergone osseointegration and are stabilized later, the peri-implant connective tissue can be differentiated and new bone formed.⁸ This clinical situation is similar to the immobilization of mobile fractured bone fragments by osteosynthesis plates in orthopedics.

Definition of Immediate Loading

There is no standardized terminology for immediate loading of dental implants in the recent literature. Even early studies showed a splinting of the placed implants using a bar in the first 3 to 4 days of healing.⁹⁻¹¹ The loading of implants may be performed in two ways: (1) by provisional crowns or partial dentures having occlusal contacts (direct immediate or occlusal, functional loading) or (2) by using a removable prostheses without occlusal contacts (indirect or nonocclusal, nonfunctional loading).

Several papers present the exact terminology currently associated with immediate loading.¹²⁻¹⁵ Van Steenberghe et al¹² differentiated *early* from *immediate* loading in their paper, presenting a concept of treatment in the maxilla in which a custom template was used and the definitive prosthesis was placed immediately after surgery. The definitive prosthesis was fabricated before surgery using precise three-dimensional planning software. Although this concept requires the use of innovative technology and advanced experience and cannot be used in daily practice by every clinician, it establishes the concept of *immediate loading* as referring to placing a definitive prosthesis with occlusal contacts immediately (within the first day) after surgery.

Degidi and Piattelli¹⁴ defined *immediate functional* and *immediate nonfunctional loading* as the placement of provisional restorations the same day or within a few days of surgery with (functional) or without (nonfunctional) occlusal contacts. When the provisional prostheses are placed between 4 days and 3 weeks after implant placement, the approach should be defined as *early loading* according to these authors.

According to studies performed by Misch,^{16,17} bone density in the bone-implant interface may be increased if the implant is loaded progressively. This is a treatment concept used when implants are placed in sites with poor bone quality. The implants are connected to their abutments without any occlusal contacts and are loaded only during chewing. Provisional crowns or partial dentures without contacts may promote bone regeneration at the interface and enhance implant stability. Bone-implant contact (BIC) can increase, and fine woven bone trabeculae can mature into coarser lamellar trabeculae, with an increase in mineral content.¹⁷ This concept should be referred to as *progressive bone load-*

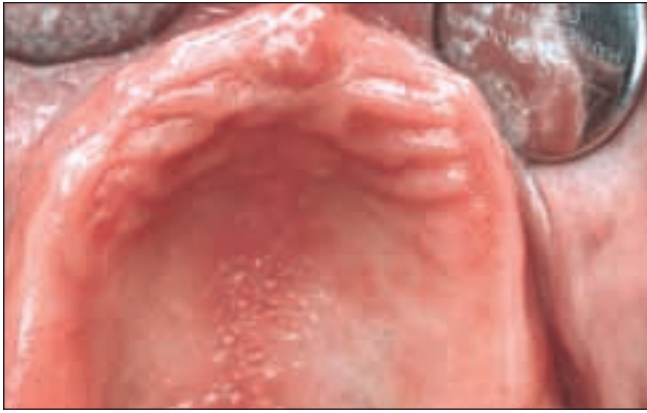

Fig 7-2f Edentulous maxilla immediately before surgery.

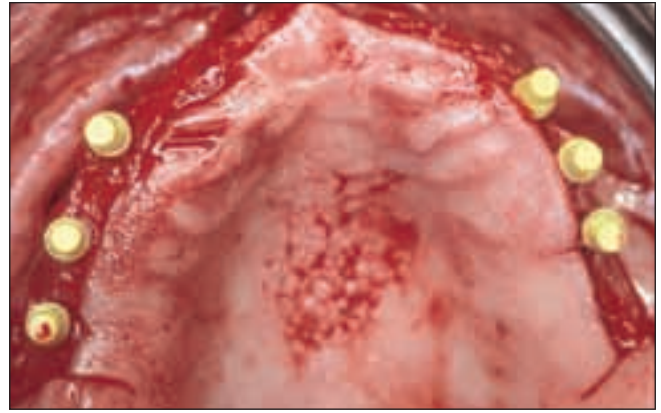


Fig 7-2g Implant placement and provisional abutments in place for correct selection of the final abutments before immediate loading.

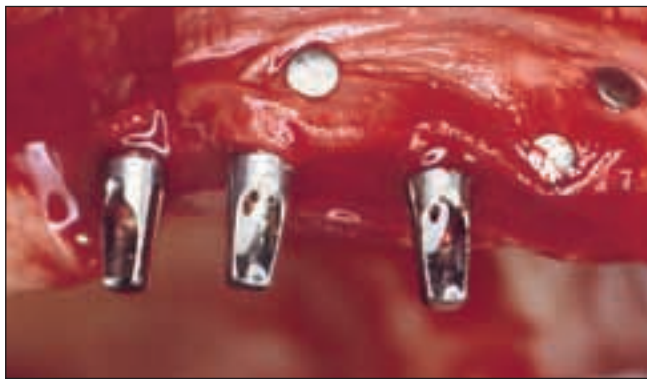

Fig 7-2h Following abutment connection with final torque, bone augmentation is performed to cover the exposed implant threads. The autogenous bone was covered with a collagen membrane.

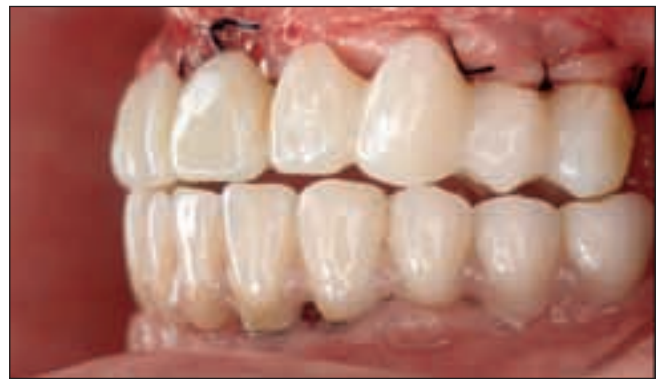

Fig 7-2i Provisional maxillary bridge in occlusion. Note the small contacts used to avoid excessive forces on the immediately loaded implants right after surgery.

Four months after loading, the patient asked for a similar treatment in the maxilla (Fig 7-2f). A prosthetic guide similar to the one used for the mandible was employed. A mucoperiosteal flap was elevated following a midcrestal incision under local anesthesia. The alveolar ridge was too narrow (less than 3-mm width) and the bone quality too compromised (very weak) to achieve optimal implant placement.

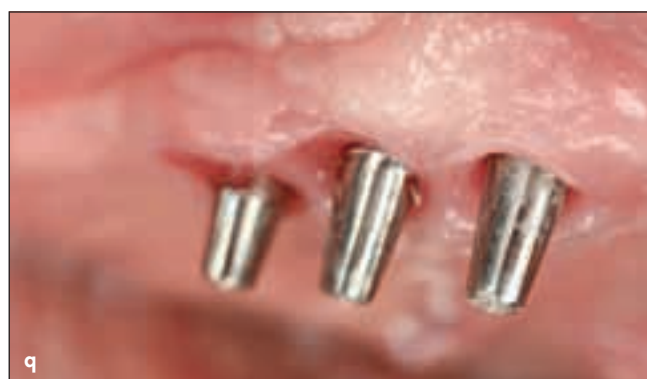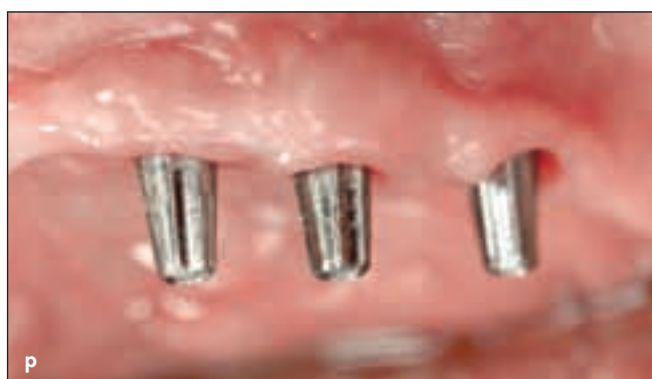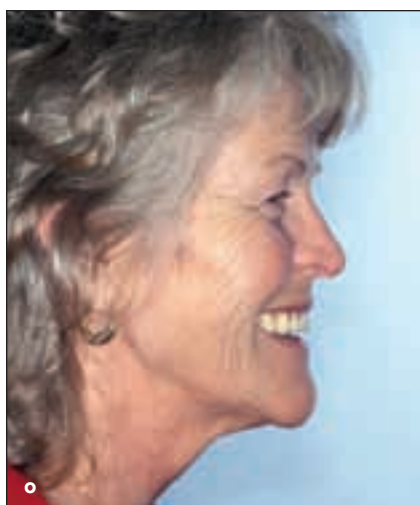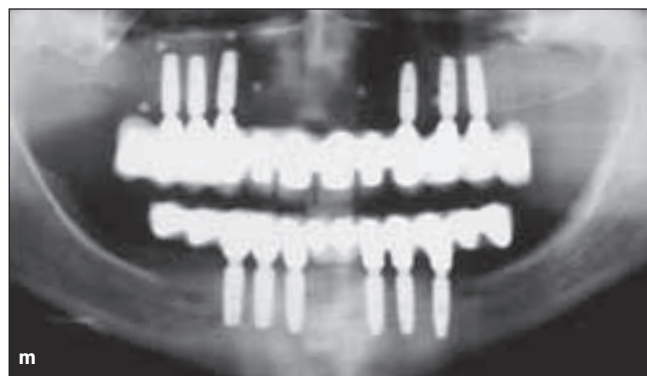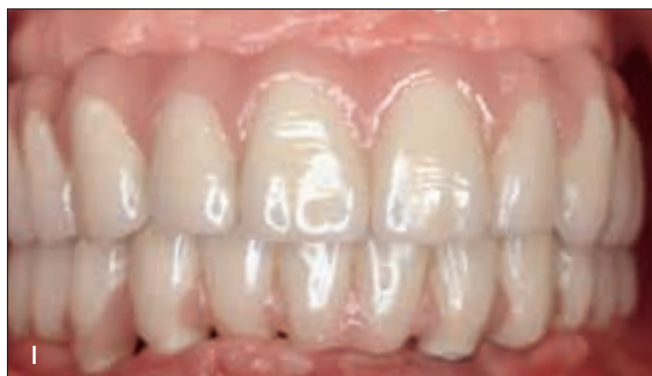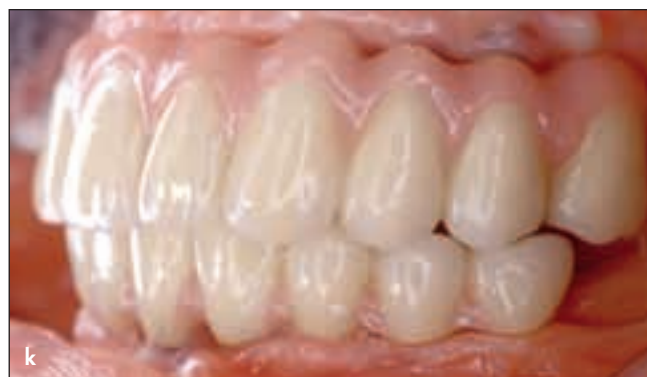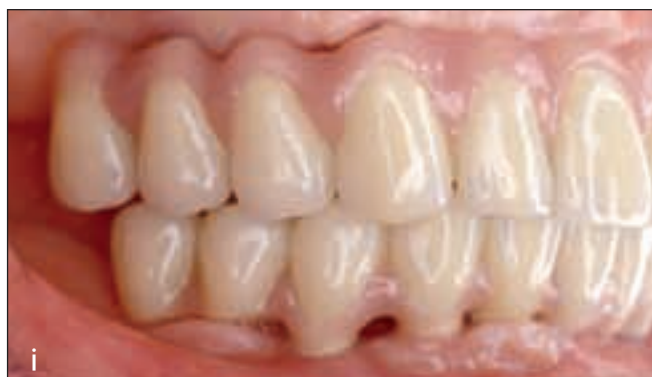The implants were placed using the protocol for the Ankylos implant system in the areas of the left and right canines through second premolars. All implants were 3.5 mm in diameter and 14 mm in length. They had excellent primary stability, but some of the threads in the buccal aspect were exposed. Autogenous bone graft was harvested from the two tuberosities using a trephine and milled with a bone mill. Temporary resin abutments were placed (Fig 7-2g) to check the parallelism and then replaced with the definitive angulated abutments using controlled torque. All implants were covered buccally with one Bio-Gide (Geistlich) collagen membrane, which was fixed in place with titanium Frios tacks (Fig 7-2h). The flap was sutured in place, and a provisional cross-arch-shaped fixed prosthesis without any distal cantilevers was fabricated chairside (Fig 7-2i).

Note: Special attention is given to ensure that the provisional prosthesis is well polished and has open

areas for sufficient plaque control and food debris removal during the initial stages of healing. A provisional prosthesis should be good but not perfect to ensure that the patient will return for follow-up visits. Missing follow-up visits could have a deleterious effect on the patient's implant prognosis.

The Periotest values were determined immediately before placement of the provisional prosthesis, and the same postoperative care instructions were given to the patient as she had received for the mandibular treatment. A symmetric balanced occlusion was used for the provisional fixed restoration in centric occlusion with only group contacts in the lateral movements of the mandible. One week after surgery, the sutures were removed. The impression for the definitive fixed implant-supported restoration was taken 4 weeks after surgery using a similar impression technique (without removing the abutments) as that used for the mandible. Finally, a radiologic examination was used to determine the crestal bone level at the time of the prosthesis delivery.

The patient was re-examined every 3 months. The restorations were removed, and the Periotest values were determined. The follow-up examination 3 years after loading in the mandible (2.5 years after loading in the maxilla) showed excellent soft tissues in all peri-implant areas as well as an esthetic result (Figs 7-2j to 7-2q).



Figs 7-2j to 7-2q Definitive implant-supported restorations 3 years after immediate loading from the right (*j*), left (*k*), and facial (*l*) aspects. (*m*) A panoramic radiograph showing the bone stability after 3 years. (*n* and *o*) The esthetic result of the restorations after 3 years of loading presents harmony with the smile line. Patient comfort was much improved. (*p* and *q*) The peri-implant soft tissues are in excellent condition.

Table 8-1 Mean clinical values obtained at test (immediately loaded) and control (delayed loaded) implant sites

Parameter	Test implants	Control implants
Plaque index	0.4 ± 0.6	0.8 ± 0.7
Sulcus bleeding index	0.5 ± 0.6	0.3 ± 0.5
Probing pocket depth (mm)	1.9 ± 0.2	2.1 ± 0.2
Keratinized mucosa width (mm)	2.5 ± 1.2	3.3 ± 1.4
Periotest value	-3.7 ± 0.9	-3.2 ± 1.3

Table 8-2 Periotest values for test and control implants at various time points

Time point	Implant group	Median	Minimum	Maximum
T0	Test	-3	-7	22*
	Control	-3	-6	1
T1	Test	-3	-8	18*
	Control	-4	-8	3
T2	Test	-3	-5	7
	Control	-3.5	-7	0
T3	Test	-3	-8	2
	Control	-3	-5	0
T4	Test	-3.7	-6	-1
	Control	-3.2	-8	0

T0, baseline; T1, 6 weeks; T2, 6 months; T3, 12 months; T4, 24 months

*Represents the same implant placed in extremely poor bone quality.

Posterior Mandible

Implant prognosis in the posterior mandible is associated with many problems because of insufficient bone quality and quantity⁸⁻¹⁰ as well as anatomical limitations that necessitate the placement of shorter implants. In addition, biomechanical factors, such as increased loading forces in this location, may be associated with higher rates of failure.¹¹ Frequent cases of peri-implantitis have also been reported in the posterior mandible.¹²

The immediate loading of implants placed in the posterior mandible may be associated with more failures because of the additional risk of micromotions at the interface, which may lead to fibrous tissue formation¹³ and, finally, implant failure. From a biomechanical point of view, increased bending moments can occur when implants are placed and loaded in the posterior part of the jaws.¹⁴ The clinical studies on immediate loading in the mandible report a high number of failures in the posterior section caused by poor bone quality in these areas.¹⁵⁻¹⁸

Tarnow et al¹⁹ placed a high number of implants in the mandible (including the posterior mandible) and did not remove the provisional restoration during the 4- to 6-month healing period. The authors recommended the use of screw-retained provisional and non-cemented restorations for easy removal and to eliminate macromovements during the healing period.¹⁹

Immediate loading in the posterior mandible was evaluated in 12 consecutive cases using a split-mouth design to compare the traditional loading protocol with the immediate occlusal loading protocol.^{4,5} Twelve patients (7 men, 5 women; mean age: 50.75 ± 7.95 years) participated in this study, which was approved by the ethics committee of the University of Frankfurt in accordance with the Declaration of Helsinki. The patients had bilateral free-end prosthetic situations in the mandible and were treatment planned for three implants distal to the canines to replace their missing teeth. One side was randomly selected as the control for placement of three de-

layed loaded implants with a progressive thread design (Ankylos, Dentsply Friadent) for submerged healing. After 3 months, the implants were exposed and loaded with splinted resin crowns. These provisional splinted crowns were replaced 6 weeks later by definitive splinted restorations. On the contralateral side, three implants that were exactly the same size as the control implants were placed and served as the test group. Abutments were placed, and the test implants were immediately loaded. Provisional crowns splinted the three implants together in each side and had occlusal contacts only in maximal intercuspation (immediate functional loading). Eccentric contacts during lateral movements of the mandible were eliminated. Canine, anterior guidance, or group function was used in all clinical cases.

Periodontal indices and bone loss were evaluated at frequent follow-up intervals. Healing was uneventful, and all implants were clinically stable. No complications or postoperative infections were observed during the observation period. No visible implant mobility was observed either immediately after surgery or during the loading period in both implant groups. After a mean loading period of 25.3 ± 3.3 months, the findings presented normal clinical values without differences between the test and control implants ($P < .05$), as presented in Table 8-1. The Periotest values (Medizintechnik Gulden) at the different time intervals are presented in Table 8-2. Twenty-nine of the 72 sites examined did not show any bone loss. These results confirm that immediate functional loading of dental implants with a progressive thread design has the same prognosis as delayed loading in the posterior mandible 2 years after loading.

Figures 8-3 and 8-4 present case examples of patients treated in the study described above. Implants placed in fresh extraction sockets (immediate implants) with immediate loading in the posterior mandible are shown in Figs 8-5 (unilateral partial denture) and 8-6 (distal cantilever partial prosthesis). Figure 8-7 presents the response of alveolar bone in a case of controlled overloading.

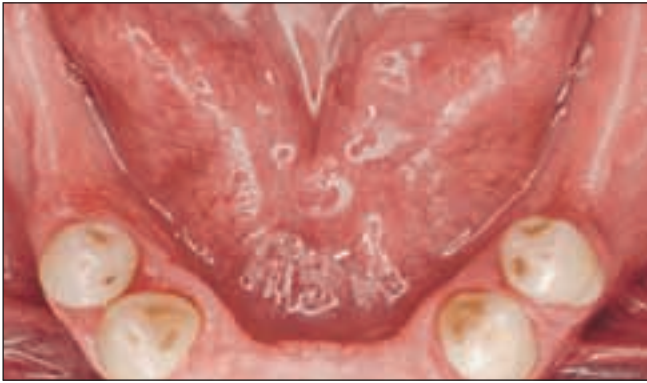


Fig 8-3a Preoperative occlusal view of bilateral edentulous posterior mandible of a 59-year-old man.

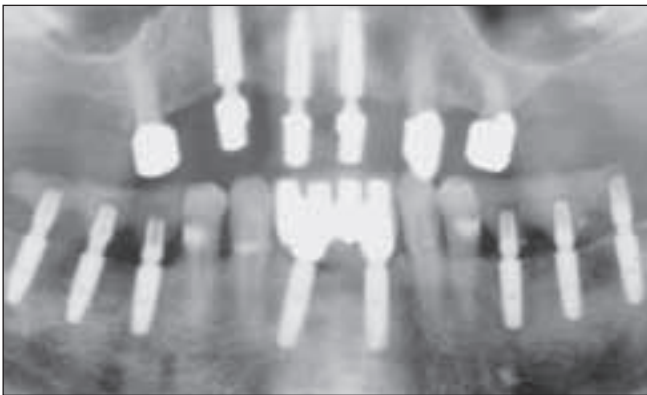


Fig 8-3c Radiograph showing bone levels after placement of provisional restorations bilaterally.

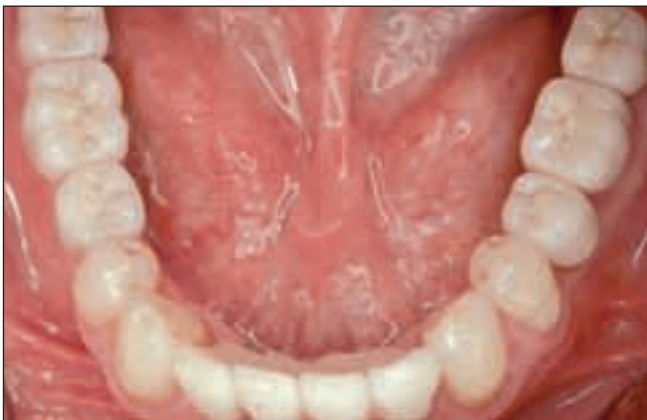

Fig 8-3e Occlusal view showing definitive restorations 5 years after placement. The left side was immediately loaded and the right side underwent delayed loading.

Fig 8-3g Panoramic radiograph 12 years after loading. Note the marginal bone loss on the right side around the implants that underwent delayed loading compared to the immediately loaded implants on the left side.

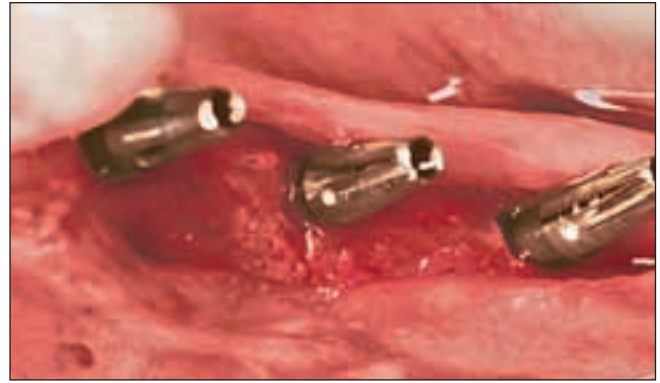

Fig 8-3b Three implants placed on the left side and connected with their abutments for immediate loading with provisional splinted crowns.

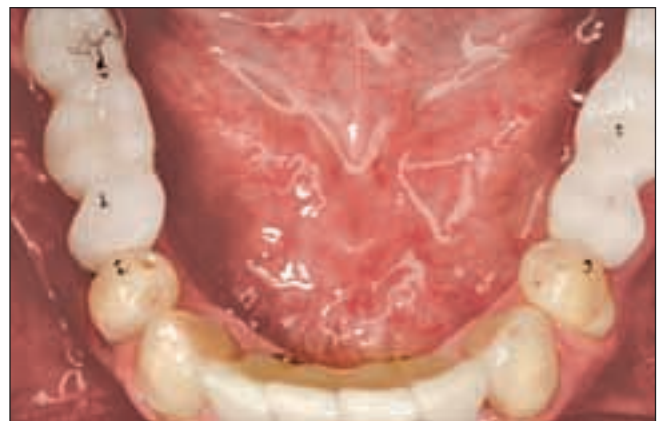

Fig 8-3d Occlusal view of provisional splinted restorations.

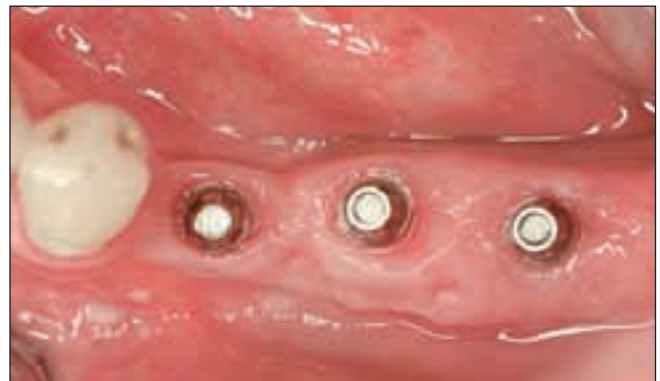

Fig 8-3f Follow-up photograph taken 5 years after loading demonstrating the healthy condition of the soft tissues around the immediately loaded implants.

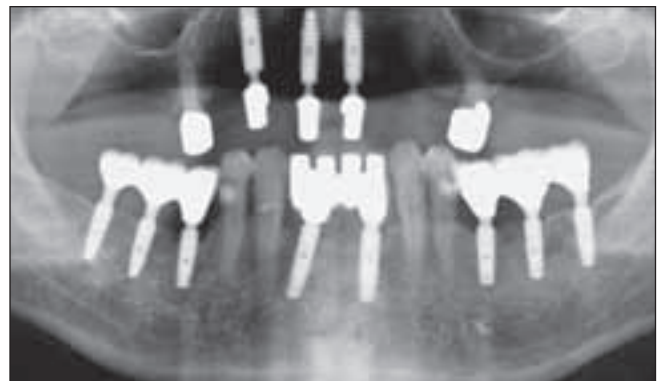

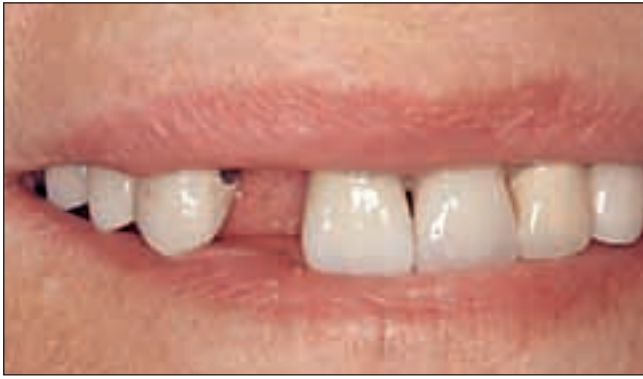


Fig 12-2a Smile line of the patient prior to surgery.

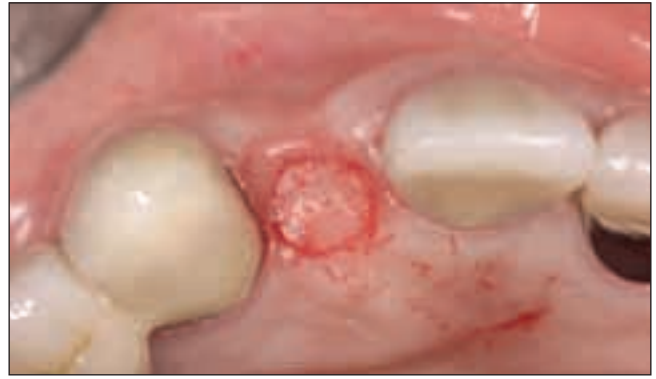

Fig 12-2b Soft tissue removed in preparation for implant placement.

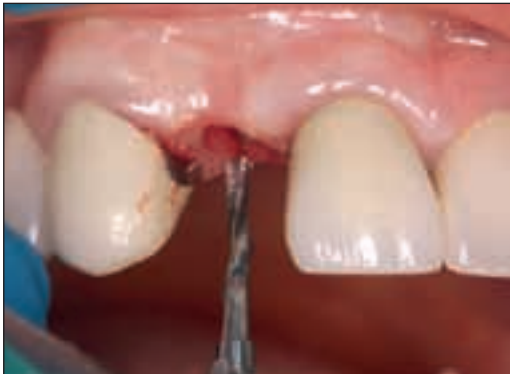

Fig 12-2c Pilot drill prior to use of osteotomes for bone spreading.

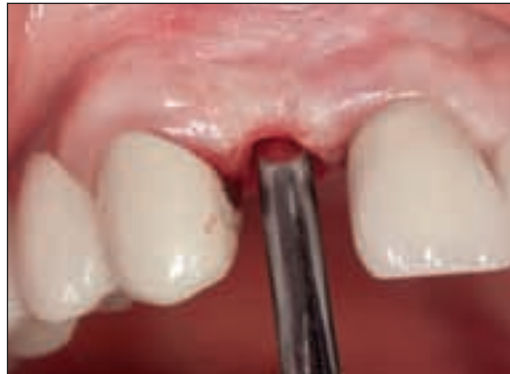

Fig 12-2d Bone-spreading technique to extend the width of the narrow alveolar ridge.




Fig 12-2e Tapered implant being placed for immediate loading.

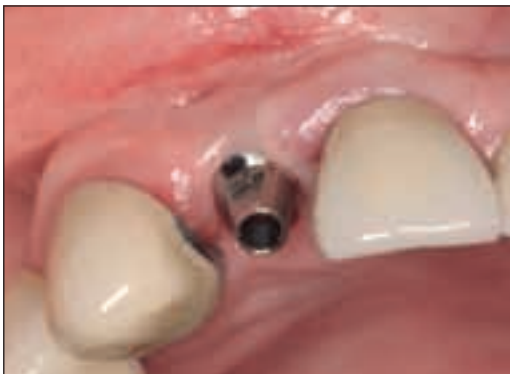

Fig 12-2f Abutment connected to the implant for immediate provisionalization.

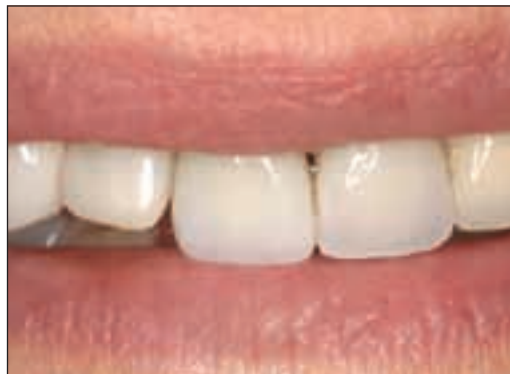

Fig 12-2g Smile line of the patient immediately after placement of the provisional crown.

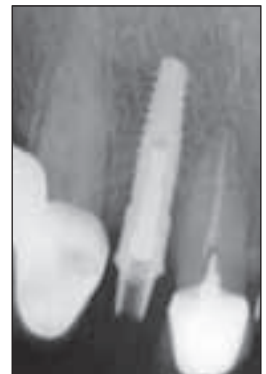

Fig 12-2h Radiographic examination following delivery of the provisional crown. (Restoration by M. Postol, New York, NY.)

Case 2: Immediate loading without platform switching

This case presents a single-tooth implant placed in the site of a maxillary right lateral incisor for a patient with a moderate smile line (Fig 12-2a). Using a prosthetic template and a soft tissue punch, the soft tissue was removed in the right lateral incisor site (Fig 12-2b). An initial drill was used before the narrow alveolar ridge

was extended with osteotomes (Ustomed) to increase the width (Figs 12-2c and 12-2d). This technique was used to avoid ridge augmentation. A tapered Osseotite implant was placed subcrestally with primary stability, and the abutment was connected using the final torque (Figs 12-2e and 12-2f). A provisional restoration was used as a template to fabricate a cement-retained resin crown (Fig 12-2g). A radiograph was taken at the end of the treatment to evaluate the bone levels (Fig 12-2h).

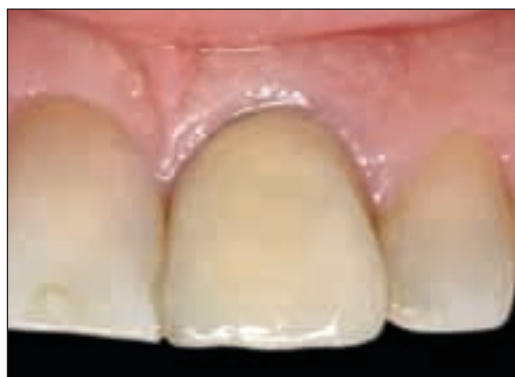

Fig 12-3a Preoperative situation following an incident in which the maxillary left central incisor was knocked.

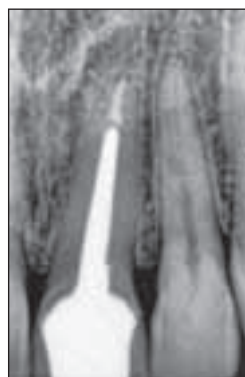

Fig 12-3b Note the fracture at the tip of the endodontic post.

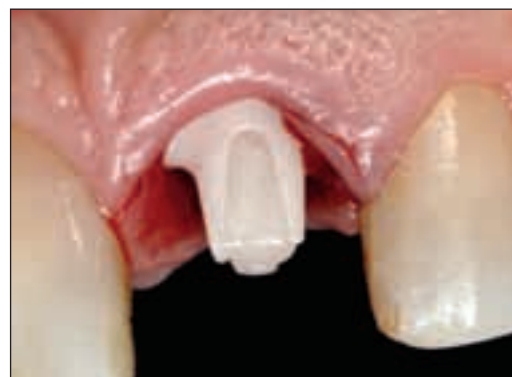
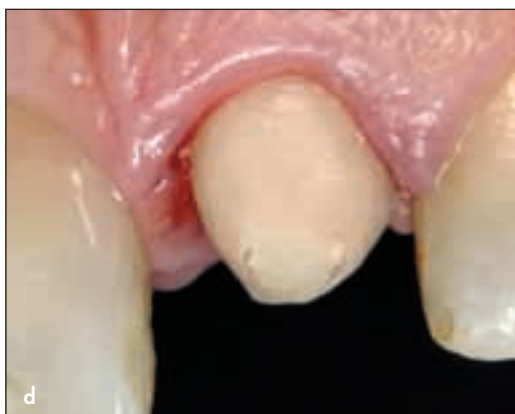
Fig 12-3c A Cercon ceramic abutment was connected to the immediate implant and fully torqued.



Figs 12-3d and 12-3e A provisional restoration was fabricated chairside and inserted on the same day.

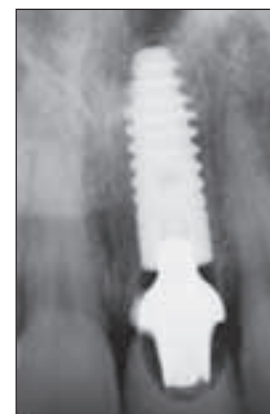
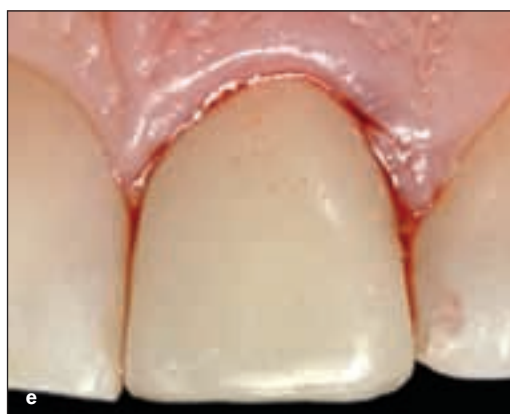
Fig 12-3f Radiographic evaluation at baseline implant placement.

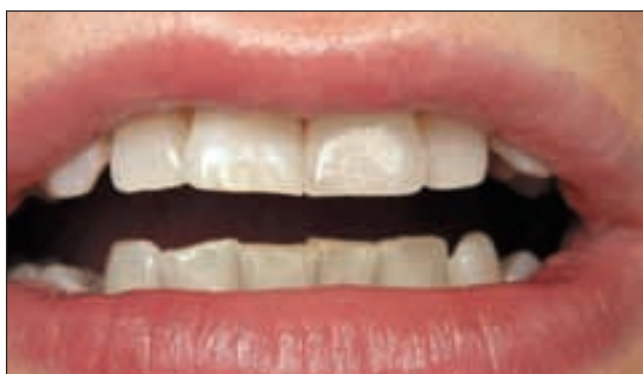

Fig 12-3g Restoration at time of delivery.

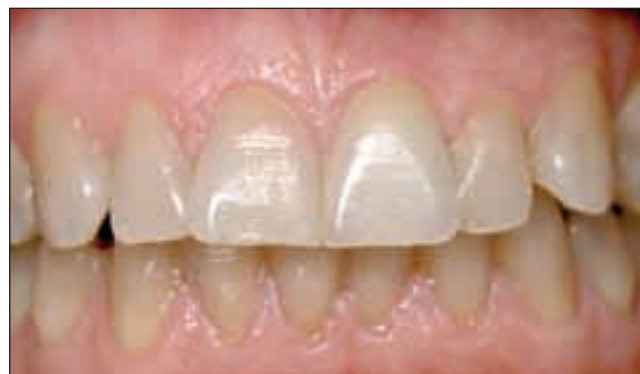

Fig 12-3h Restoration at 4-year follow-up. (Surgery and prosthodontics by N. Saynor, Manchester, UK.)

Case 3: Esthetic immediate loading using a customized ceramic abutment and platform switching

A 38-year-old woman presented 2 days after trauma to her anterior maxilla. She experienced pain in the labial sulcus around her maxillary left central incisor as well as pain on biting (Fig 12-3a). Radiographic examination revealed a root fracture at the tip of the fabricated post (Fig 12-3b). The tooth was extracted atraumatically with periostomes. After socket debridement and osteotomy

preparation with burs and osteotomes, an Ankylos implant (4.5-mm diameter and 14 mm long) was placed in the fresh extraction socket and torqued to 35 Ncm. Anorganic bovine bone (Bio-Oss) was placed facially. A Cercon ceramic abutment (Dentsply Friadent) was connected with a final torque and was never removed after this (Fig 12-3c). A provisional acrylic restoration was made at the time of extraction and implant placement and kept out of occlusal contact (Figs 12-3d to 12-3f). The final restoration was constructed 14 weeks after implant placement and presented an excellent long-term result (Figs 12-3g and 12-3h).

Index

Page numbers followed by “f” indicate figures; those followed by “t” indicate tables; those followed by “b” indicate boxes

A

- Abutments
 - ceramic, 135, 135f
 - connection of, 81f, 142f
 - provisional, 70f
 - telescopic, 61, 61f–62f
- Acid-etched implant surface, 31f, 31–32
- Advanced immediate loading, in maxilla, 73f–75f, 73–75
- Advanced lateral and vertical augmentation
 - in mandible, 92–96, 93f–96f
 - in maxilla, 96, 97f–99f
- Alveolar ridge
 - augmentation of, 99, 101, 101f–105f
 - deficiency of, 97f
 - expansion of, 80f
 - tapered implants in, 143
- Angiogenesis, 3
- Animal studies
 - bone response, 43–44, 45f
 - peri-implant soft tissue response, 46–48
- Anterior mandible
 - implant-supported bar-retained overdentures in, 55–56, 56f
 - telescopic-retained overdentures in, 56, 57b, 57f–60f, 58
- Appositional growth, 6
- Atrophic mandible, 75f–77f, 75–76, 157f–159f, 157–159

B

- Bar-retained overdentures, implant-supported, 55–56, 56f
- Bar-retained restorations, 12, 13f, 20
- Bioceramic coating, 33–35, 35f
- Biologic width, 47
- Biomaterials, 28
- Biomechanics, 19
- Blood clot stabilization, 131
- Bone
 - anatomy of, 1
 - formation of, 4
 - healing of, 4–6, 5f, 8, 17
 - loading effects on, 4
 - microvasculature of, 2–3
 - physiology of, 3–4
 - remodeling of, 1–2, 19
 - strain on, 3f, 3–4
- Bone augmentation
 - alveolar, 99, 101f
 - single-tooth implants after, 137, 137f–139f, 140f–141f, 140–141
- Bone grafting
 - in heavy smoker, 114, 114b
 - in mandible, 63–68, 64f–68f
 - in maxilla, 69f–72f, 69–72
 - single-implant placement after, 143, 143f
- Bone quality
 - description of, 7
 - immediate loading affected by, 18, 18f
 - poor, drilling in, 173
- Bone response
 - animal studies of, 43–44, 45f
 - human studies of, 48–49, 49f

- Bone-implant contact, 6–8, 11, 41t
- Bone-implant interface
 - bone density at, 11
 - histomorphometric analysis of, 43
 - micromovement at, 40–41
- Brånemark implants, 17
- Buccal implant placement, 174, 174f

C

- Calcium phosphate discrete crystalline deposition, 34, 35f
- Capillaries, 2–3
- Caries, 160f–161f, 160–161
- Cement line, 6
- Cement-retained provisional restorations, 175
- Ceramic abutment, 135, 135f
- Clot formation, 6, 7f
- Complications
 - buccal implant placement, 174, 174f
 - drilling in poor-quality bone, 173
 - implants placed in fresh extraction sockets, 174–175
 - intraoperative, 173–175, 174f
 - overtorquing of implant, 173–174, 174f
 - postoperative, 175
 - prosthetic, 175–176
- Cone beam computed tomography, 98f
- Connective tissue contact, 47–48
- Contact osteogenesis, 8
- Cortical bone, 1–2
- Corticocancellous block
 - maxilla augmentation using, 97f
 - maxilla loading after horizontal augmentation with, 89–92, 90f–92f
- Cross-arch implant-supported prosthesis, 124, 125f–128f, 127
- Cylindric implants, 40f

D

- Delayed loading
 - animal studies of, 44
 - histologic analysis of, 44
- Diet protocol, 78, 175
- 1,25-Dihydroxyvitamin D₃, 2
- Dynamic osteogenesis, 5f, 5–6

E

- Early loading, 11, 41
- Edentulous arches, 77–78
- Edentulous patients. *See also* Partial edentulism.
 - implant-supported bar-retained overdentures in, 55–56, 56f
 - mandible, 112f
 - maxilla, 112f
- Extraction sockets
 - fresh, implant placement in
 - advanced protocol for, 147, 148f–150f, 153f–154f, 153–154
 - case reports, 147–169, 148f–170f
 - complications of, 174–175
 - maxilla, 151f–157f, 151–156
 - multiple caries, 160f–161f, 160–161
 - studies of, 146–147
 - healing of, 145–146
 - remodeling of, 146

F

Fibrin clot, 6, 7f
Fixed restorations, 14–15

G

Grafted bone, maxilla loading after horizontal augmentation with, 89–92, 90f–92f. *See also* Bone grafting.
Grit blasting, 31f, 31–33, 35
Growth factors, 2
Guided bone regeneration, 93

H

Haversian systems, 44
Healing, of bone, 4–6, 5f, 8, 17
Hemiosteonal remodeling, 1
HIV-positive patients, 115, 116f–118f, 119†
Hong Kong Bridge Protocol, 15
Horizontal augmentation with corticocancellous block, maxilla loading after, 89–92, 90f–92f

I

Immediate loading
 definition of, 11–12
 functional, 11
 methods of, 11
 nonfunctional, 11
 rationale for, 12
 survival rates, 12–13
Immediate provisionalization, 12
Immediately loaded implants
 bone formation around, 44, 45f
 bone response to. *See* Bone response.
 description of, 17
 histologic findings, 44, 49f
 peri-implant soft tissue response of, 46
 survival rate of, 131
Implant(s)
 buccal placement of, 174, 174f
 cylindric, 7
 healing of, 17
 immediate, 17
 narrow-diameter, 7
 nontapered, 49–51, 50f
 overtorquing of, 173–174, 174f
 in partially edentulous patients, 16
 removal of, 101
 scalloped, 132
 screw-type, 12, 39, 41, 50
 single-tooth. *See* Single-tooth implants.
 tapered. *See* Tapered implants.
 threaded. *See* Threaded implants.
 titanium-free, 7
Implant design
 healing affected by, 7
 immediate loading affected by, 17
Implant retrieval analysis, 30
Implant stability
 definition of, 12
 primary, 6–8, 13, 39–40, 78, 173
 secondary, 39
Implant surface
 acid-etched, 31f, 31–32
 bioceramic coating, 33–35, 35f
 biocompatibility testing of, 28–29
 bone metabolism affected by, 43
 calcium phosphate discrete crystalline deposition, 34, 35f
 clinical evaluation of, 29–30
 definition of, 27
 grit blasting of, 31f, 31–33, 35

 illustration of, 7f
 immediate loading affected by, 17–18
 machined, 31f
 modifications of, 30–35
 nanotechnology application to, 34–35
 osseointegration affected by, 27
 plasma-sprayed hydroxyapatite, 30, 33–34
 rough, 7, 30–31
 saline-blasted, large-gritty, acid-etched, 32
 testing of, 28–30
 titanium plasma-sprayed surface, 13, 17, 20, 30, 31f
 topographic modifications of, 30–33
 treatments for changing, 27
Implant-abutment connection, 20
Intraoperative complications, 173–175, 174f
Ion beam-assisted deposition, 34

J

Junctional epithelium, 47–48

L

Lacunocanalicular system, 4
Lamellar bone, 4, 5f, 44
Lateral and vertical augmentation, advanced
 in mandible, 92–96, 93f–96f
 in maxilla, 96, 97f–99f

M

Mandible. *See also* Anterior mandible; Posterior mandible.
 after advanced lateral and vertical augmentation in, 92–96, 93f–96f
 atrophic, 75f–77f, 75–76, 157f–159f, 157–159
 bone quality in, 18
 edentulous, 112f
 of heavy smoker, 108–110, 110f–114f
 peri-implant soft tissue in, 113f
 posterior, 82, 83f–87f
Maxilla
 advanced lateral and vertical augmentation in, 96, 97f–99f
 bone grafting in, 69f–72f, 69–72
 bone quality in, 18
 edentulous, 112f
 of heavy smoker, 108–109
 immediate loading in
 advanced, 73f–75f, 73–75, 164–165
 with cross-arch implant-supported prosthesis and bilateral sinus elevation, 124, 125f–128f, 127
 fresh extraction sockets, 151f–157f, 151–156
 after horizontal augmentation with corticocancellous block, 89–92, 90f–92f
 sinus elevation performed simultaneously with, 129, 129f–130f, 151f–152f, 151–152, 164f–166f, 164–165
 orthodontic extrusion in, 167f–170f, 167–168
 peri-implant soft tissue in, 113f
 posterior, 79–81, 80f–81f
Maxillary left lateral incisor, 134, 134f
Mechanostat theory, 3–4
Metal-ceramic restorations, 67
Midcrestal incision, 77

N

Nanoindentation, 29
Nanotechnology, 34–35, 35f
Narrow-diameter implants, 7
Nontapered implants, 49–51, 50f

O

Occlusal contacts, 132
Omnivac shell technique, 91f–92f, 91–92, 115

- One-stage protocol, 46
- Osseointegration
 animal studies of, 43–44
 definition of, 1
 factors that affect, 29, 43
 implant surface effects on, 27
 mechanisms of, 4
- Osteoblasts, 2, 4
- Osteoclasts, 2, 4
- Osteoconduction, 6, 7f
- Osteocytes, 2, 4
- Osteogenesis, 5f
- Osteotomy, 6
- Overdentures, 12–14, 13f
 implant-supported bar, 55–56, 56f
 telescopic-retained, 56, 57b, 57f–60f, 58
- Overtorquing, of implant, 173–174, 174f
- P**
- Partial dentures, 16
- Partial edentulism
 immediate loading in, 163, 163f
 implant placement in, 16
 telescopic abutments in, 61, 61f–62f
- Peri-implant soft tissues
 in maxilla, 113f
 response of, 46–48, 86f
- Periodontal disease, 107, 153
- Plasma-sprayed hydroxyapatite, 30, 33–34
- Platelet-derived growth factor, 6
- Platform switching, 56, 135, 135f, 143
- Posterior implants, 15
- Posterior mandible
 advanced augmentation in, 99, 100f–101f
 immediate loading in, 82, 83f–87f, 99, 100f–101f
 resorption in, 93f
 single-tooth implants in, 133, 133f
- Posterior maxilla, 79–81, 80f–81f
- Primary implant stability, 6–8, 13, 39–40, 78, 173
- Progressive bone loading, 11–12
- Prostacyclin, 2
- Prostaglandin E₂, 2
- Prosthetic complications, 175–176
- Provisional abutments, 70f
- Provisional restorations
 cement-retained, 175
 fixed, 20, 78
 metal reinforcement of, 175, 175f
 screw-retained, 175
- R**
- Remodeling of bone, 1–2, 19
- Removable restoration, 156, 156f–157f
- Resonance frequency analysis, 40
- Rough-surface implants, 27, 30–31
- S**
- Saline-blasted, large-gritty, acid-etched implant surface, 32
- Scalloped implants, 132
- Screw-retained provisional restorations, 175
- Screw-type implants
 case reports of, 50
 description of, 12, 39, 41
- Secondary implant stability, 39
- Self-tapping implants, 40
- Single-tooth implants
 in adolescent patient, 142, 142f
 in augmented bone, 137, 137f–139f
 case reports of, 133f–144f, 133–144
 clinical results of, 131, 132t
 customized ceramic abutment and platform switching, 135, 135f
 description of, 16, 131
 hard and soft tissue augmentation with, 140f–141f, 140–141
 maxillary left lateral incisor, 134, 134f
 in posterior mandible, 133, 133f
 tapered implants, 136, 136f–137f
- Sinus elevation, simultaneous
 autograft for, 122, 123f–124f
 case reports of, 122–129, 123f–130f
 cross-arch implant-supported prosthesis and, 124, 125f–128f, 127
 lateral window preparation for, 122f
 in maxilla, 124, 125f–130f, 127, 129, 151, 151f–152f, 164f–165f, 164–165
 radiographs of, 122f
 technique for, 121
- Smokers/smoking
 bone grafting in, 114, 114b
 clinical study in, 107–108
 immediate loading in, 107–114
 mandible of, 108–110, 110f–114f
 maxilla of, 108–109
 periodontal disease risks, 107
- Soft tissue
 adherence of, 1
 augmentation of, single-tooth implants with, 140f–141f, 140–141
 contouring of, 167f–170f, 167–168
 peri-implant
 in maxilla, 113f
 response of, 46–48, 86f
- Splinting, 20
- Static osteogenesis, 5–6
- Strain, 3f, 3–4
- Stratified squamous epithelium, 46
- Straumann implants, 40, 40t, 136, 136f
- Subcrestal placement, 132
- Surface of implant. *See* Implant surface.
- T**
- Tapered implants
 in alveolar ridge, 143
 case reports of, 51–52, 136, 136f–137f
 description of, 17, 40f, 41
 single-tooth, 136, 136f–137f
- Telescopic abutments, 61, 61f–62f
- Telescopic-retained overdentures, in anterior mandible, 56, 57b, 57f–60f, 58
- Threaded implants
 advantages of, 17
 description of, 7
 fixed restorations on, 14
- Titanium plasma-sprayed implants, 13, 17, 20, 30, 31f
- Titanium-free implant, 7
- Trabecular bone, 44, 45f
- Transitional implants, 15
- V**
- Vascular endothelial growth factor receptor, 3
- Vertical augmentation. *See* Lateral and vertical augmentation, advanced.
- W**
- Wolff's law, 3
- Woven bone, 4, 5f